

## OSTEOSARCOMA IN THE MANDIBLE, AN UNUSUAL LOCATION FOR THE PRIMARY TUMOR

CRISTÓVÃO MARCONDES DE CASTRO RODRIGUES, NATÁLIA VIEIRA SANTOS,  
WALACY VAMBASTER SILVA BORGES, JÉSSICA MATA DO NASCIMENTO, IZABELLA SOL

Department Oral and Maxillofacial Surgery and Traumatology, Hospital de Clínicas,  
Federal University of Uberlândia, Uberlândia, Minas Gerais, Brazil

E-mail: cristovaomarcondes@gmail.com

Osteosarcomas rarely affect the jawbones, and are challenging to diagnose and treat. We report a case of a 23-year-old male patient, admitted to the medical emergency service due to edema located in the left mandibular region. Patient denied comorbidities and known allergies, an oral panoramic radiograph was performed, which exposed radiopacity in sunlight, a pathognomonic sign of osteosarcoma as demarcation in red highlights (Fig. 1). On intra-oral clinical examination, the lesion presented exophytic characteristics, necrotic aspect and edges with hardened consistency as indicated by the red arrow.

The patient was referred to the head and neck surgery team, which requested a computed tomography to assess the extent of the lesion, where it was possible to observe in the sagittal, coronal and axillary sections the large dimensions that the tumor presented and the level of structural impairment (Fig. 2 A, B and C). After confirming the diagnosis, he resected the tumor and started radiotherapy and chemotherapy. This case is the first treated and documented in the country's unified health system. Patient followed between 2019 and 2021. In August 2021, the patient died due to complications arising from the tumor.

Figure 1 |

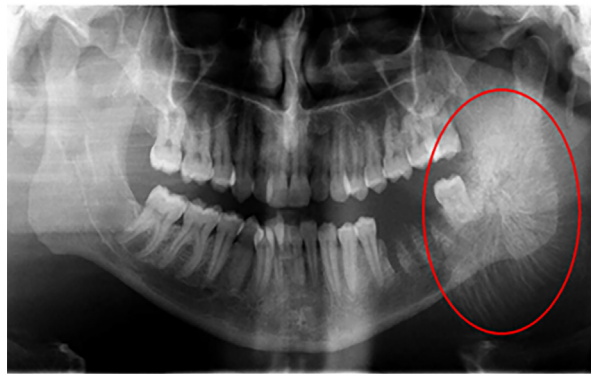


Figure 2 |

