

OPEN SURGERY FOR URETHRAL FOREIGN BODY

MARTÍN MAQUEDA VOCOS, NICOLÁS A. BONANNO, LEANDRO BLAS, NICOLÁS VILLASANTE

Departamento de Urología, Hospital Alemán de Buenos Aires, Argentina

Abstract The introduction of foreign bodies in the urethra are uncommon. Given its rarity, the approach to this condition is not standardized but it is highlighted that minimally invasive procedures should be prioritized depending on its feasibility. In the present study, we report a case of a 60-year-old male patient with bipolar disorder and a foreign body impacted in the bulbar urethra with open surgical resolution after a failed endoscopic treatment. We perform an analysis into the diagnostic and therapeutic methods used, with postoperative results.

Key words: urethral foreign body, psychiatric disorder, cystoscopy, urethroplasty

Resumen *Tratamiento quirúrgico convencional de cuerpo extraño uretral*

La introducción de cuerpos extraños uretrales es poco frecuente, razón por la cual, la mayoría de las publicaciones disponibles en la literatura son reportes de casos aislados o pequeñas series con gran heterogeneidad. Existen distintas aproximaciones frente a esta afección, desde métodos menos invasivos hasta cirugías abiertas más complejas. Presentamos un caso de cuerpo extraño impactado en uretra bulbar con el objetivo de analizar métodos diagnósticos empleados y aproximaciones terapéuticas concluyendo en la resolución quirúrgica convencional. Se evaluaron resultados postoperatorios.

Palabras clave: cuerpo extraño uretral, desorden psiquiátrico, citoscopia, uretroplastía

The introduction of foreign bodies in the urethra is a rare occurrence that urologists may face, even though it has been described since ancient times¹, and numerous cases of self-inflicted urethral foreign bodies (UFBs) reported. Most of the publications available are case reports and small series of cases with a great diversity²⁻⁵. The most frequent motivation is erotic self-stimulation, however, psychiatric pathology, sexual violence and drug abuse may be present simultaneously^{2,4}.

Given its rarity, the approach to this pathology is not standardized⁶ but it is highlighted in the literature that minimally invasive procedures should be prioritized⁷.

We report a case of a patient with a foreign body impacted in the bulbar urethra with open surgical resolution after a failed endoscopic treatment, analyzing diagnostic and therapeutic methods used, with postoperative results.

Clinical case

A 60-year-old male patient with a history of bipolar disorder presented to consult with dysuria and difficulty to void despite

self-prescribed antibiotic treatment. At the interrogation, he referred to previous urethral instrumentation for erotic purposes four months ago with an undetermined object, removed according to the patient's statement. Physical examination revealed abdominal and scrotal scars secondary to self-inflicted injuries during erotic stimulation. An induration was palpated at penoscrotal junction level on the topography of the bulbar urethra that extended toward the bladder neck. Neither its size, shape nor mobility could be confirmed. Poorly visible on X-ray, point of care ultrasound showed an indeterminate, tubular foreign body in the bulbar urethra but its size could not be defined. Computed tomography of the pelvis showed a 10 cm foreign body of blunt edges in the bulbar and pendulous urethra (Fig. 1). The patient preserved spontaneous urination with positive multiresistant *Escherchia coli* urine culture, which was treated with intravenous antibiotics.

In-office, flexible cystoscopy (14Fr) was performed, visualizing scarring and decrease caliber of the pendulous urethra that allowed the passage of the instrument. At the level of the bulbar urethra, severe mucosal edema and narrowing did not allow progression and direct vision of the foreign body was not possible.

Under general anesthesia, simultaneous urethroscopy and percutaneous cystoscopy were performed. An initial cystourethrography showed passage of contrast through the tubular element in the bulbar and membranous urethra with a proximal filiform path to the bladder. Severe edema of the bladder neck and bleeding mucosa at instrumentation hindered the procedure. Attempts to grasp the foreign body with cystoscope forceps failed because it was slippery, therefore open surgery was decided.

With the patient placed in lithotomy position, a 3 cm longitudinal incision was made at the penoscrotal junction level by palpation of the indurated area (distal end of the UFB). A

Received: 21-III-2022

Accepted: 30-III-2022

Postal address: Martín Maqueda Vocos, Hospital Alemán de Buenos Aires. Av. Pueyrredón 1640, 1118 Buenos Aires, Argentina
e-mail: maquedavocos@gmail.com

longitudinal ventral urethrotomy exposed the distal end of a plastic UFB with smooth edges (Fig. 2), which was extracted by gentle traction (10-cm plastic tubular sectioned segment of 20 Fr silicone bladder catheter). Stricture of the urethra proximal to the urethrotomy allowed passage of a 12 Fr bladder catheter. A two-plane closure with Monocryl 4-0 over the catheter was done. Finally, a 10 Fr suprapubic catheter was placed.

The patient was discharged on the same day of the procedure with no postoperative complications during follow-up. Catheters were removed in the second postoperative week with previous cystourethrography showing no leaks and correct progression of the contrast to the bladder. At six months follow up, flowmetry was performed showing a Q max of 14.4 ml/sec and a Q average of 8.6 ml/sec.

Fig. 1.– CT, sagittal view of a tubular image of dense walls in topography of the bulbar and membranous urethra, approximately (104 mm) in length, compatible with a foreign body

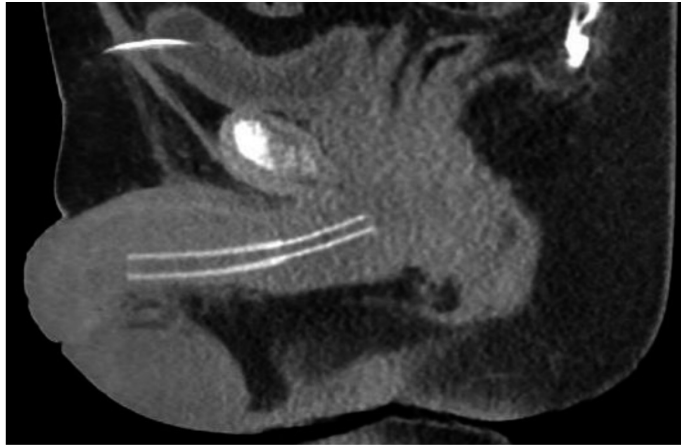
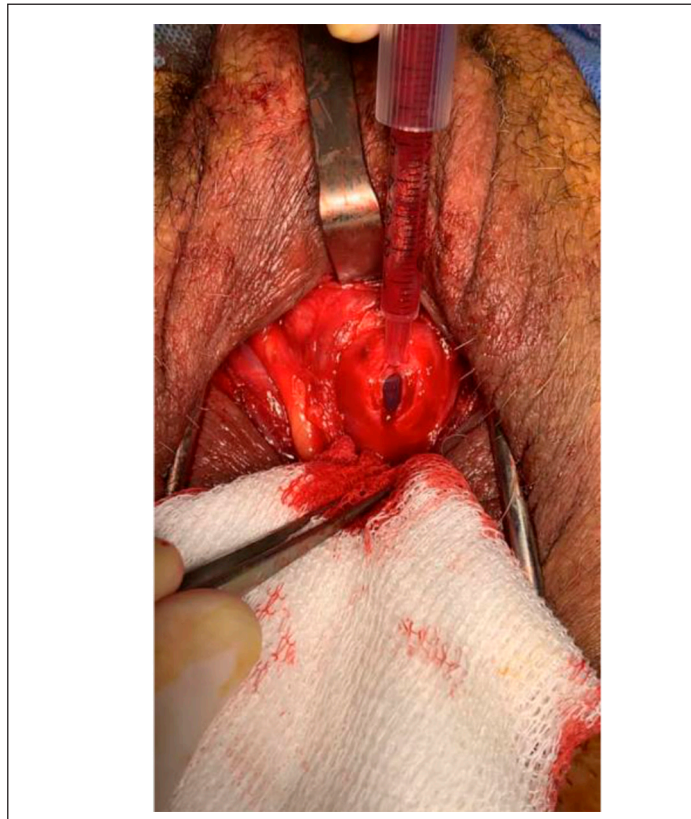


Fig. 2.– Dissection of 2 cm in bulbar urethra over indurated area and opening of the same in its ventral face through longitudinal incision of 1 cm. Externalization of the foreign body



Discussion

The most commonly reported motivation for self-insertion of UFBs is erotic auto-stimulation^{6, 8}. Association with mental and personality disorders is frequent. In a 2016 multicentric review, 86% of patients carried a previous psychiatric diagnosis, including bipolar, schizoaffective disorder, or antisocial personality trait². Also, of 27 patients, six had recurrent foreign body insertion, with four patients inserting foreign bodies twice, and two patients inserting items three times. This highlights the need for an initial psychiatric evaluation or during follow-up to identify and treat those with an underlying mental disorder⁵. Patients may delay the consultation due to embarrassment or late onset of symptoms, sometimes leading to advanced conditions requiring more invasive treatments⁹, as seen in our case.

Various objects can get trapped in the urethra, challenging the urologist with the correct diagnosis and therapeutic approach. Multiple objects such as probes, metal tools, and various organic elements had been reported^{4, 9, 10}.

As complementary studies, urine culture should be requested to establish adequate antibiotic treatment. Pelvic radiography and ultrasound are adequate initial methods for radiopaque or echogenic elements¹¹. In the case of plastic or organic elements, their correct visualization is difficult, so that a CT scan may be necessary.

The size, shape, location, material, and mobility of foreign bodies must be carefully diagnosed. Before any maneuver, treatment should be selected according to these characteristics. After an analysis of 35 cases, Palmer et al. present an algorithm for UFB management². Bogdanovic et al. reviewed it, and the authors suggest that small (< 1 cm), mobile foreign bodies with smooth surfaces located in the penile urethra with no urethrorrhagia are suitable for attempting manual removal⁷. Not having any of these criteria above, should advise the physician on the next treatment option.

With advances in endourology, most cases can now be managed endoscopically^{7, 12}. Special care must be taken in the morphology and edges of these elements, capable of producing cutting or tearing damage to the tissues during extraction⁵. In a similar case recently published, Albakr et al. successfully removed a plastic UFB through simultaneous retrograde urethroscopy and percutaneous cystoscopy¹³. UFBs can generate great local inflammatory response and time since the introduction is a predictor. As shown in our case, despite having an UFB feasible to endoscopic retrieval by size and shape, open surgery was needed. We believe these factors are decisive for correct endoscopic management.

More invasive foreign body extraction procedures may be required (urethrotomy for pendulous urethral, suprapubic cystotomy for posterior urethral or bladder foreign bodies)^{2, 9}. It is preferred to avoid open procedures to prevent possible complex complications (hematomas, infection, abscesses, fistula, urethral stricture or diverticulum, incontinence, and

erectile dysfunction)^{14, 15}. Non the less, urethrotomy is a feasible option. It is recommended to place a suprapubic bladder drainage for correct urinary diversion. Our patient presented no complications during follow-up.

In conclusion, urethral foreign bodies are rare, but given ongoing case reports, they continue to appear to the urologist. Given the high prevalence of associated psychiatric disorders, a thorough evaluation of motivations and psychosocial issues is crucial, which may prevent future episodes. After the failure of minimally invasive treatment, open surgery is feasible with good results. Larger series are still needed to evaluate this therapeutic option.

Conflict of interest: None to declare

References

1. Attwater HL. The history of urethral stricture. *BJU* 1943; 15(02): 39-51.
2. Palmer CJ, Houlihan M, Psutka SP, Ellis KA, Vidal P, Hollowell MP. Urethral foreign bodies: clinical presentation and management. *Urology* 2016; 97: 257-60.
3. Ogbetere FE, Irekpita E. A self-insertion of an uncommon urethrovaginal foreign body for autoerotism. *Niger J Surg* 2021; 27: 81-3.
4. Ray RP, Ghosh B, Pal DK. Urethral foreign body in an adolescent boy: report of two rare cases and review of literature. *Int J Adolesc Med Health* 2015; 27: 463-5.
5. Rahman NU, Elliott SP, McAninch JW. Self-inflicted male urethral foreign body insertion: endoscopic management and complications. *BJU Int* 2004; 94: 1051-3.
6. Van Ophoven A, deKernon JB. Clinical management of foreign bodies of the genitourinary tract. *J Urol* 2000; 164: 274-87.
7. Bogdanović J, Sekulić V, Trivunić-Dajko S, Herin R. Re: Palmer et al.: urethral foreign bodies: clinical presentation and management (Urology 2016; 97: 257-260). *Urology* 2017; 100: 256-8.
8. Rieder J, Brusky J, Tran V, Stern K, Aboseif S. Review of intentionally self-inflicted, accidental and iatrogenic foreign objects in the genitourinary tract. *Urol Int* 2010; 84: 471-5.
9. Naidu K, Chung A, Mulcahy M. An unusual urethral foreign body. *Int J Surg Case Rep* 2013; 4: 1052-4.
10. Sukkarieh T, Smaldone M, Shah B. Multiple foreign bodies in the anterior and posterior urethra. *Int Braz J Urol* 2004; 30: 219-20.
11. Frier J, Nicholas E, Klawitter P. Case report: using point-of-care ultrasound as a tool to identify a urethral foreign body. *Clin Pract Cases Emerg Med* 2021; 5: 39-42.
12. Abouelazayem M, Kamel AA, Ghanem M, Abu-El-Azayem K. Self-insertion of urethral foreign body: a simple endoscopic technique for removal of a metal forceps from male urethra. *Urol Case Rep* 2019; 24: 100852.
13. Albakr A, Al Rumaihi K, Al Ansari A, Alobaidy A. Combined percutaneous and transurethral cystoscopy for large urethral foreign bodies: a case report and literature review. *Urol Case Rep* 2021; 37: 101625.
14. Mannan A, Anwar S, Qayyum A, Tasneem RA. Foreign bodies in the urinary bladder and their management: a Pakistani experience. *Singapore Med J* 2011; 52: 24-8.
15. Simms A, Chappidi M, Yang H, Hampson L, Breyer B, Cohen AJ. Urethral defect in setting of recurrent urethral foreign body insertion. *Urology* 2020; 137: e12-e13.