

POST-COVID-19 SUPERIOR MESENTERIC ARTERY AND JEJUNAL BRANCHES THROMBOEMBOLISM

VINÍCIUS C. PARRELA¹, ANDERSON L. SIMONI², JOÃO H. A. SILVA³,
SÍLVIA M. P. CAMILO⁴, GEISA P. M. GOMIDE⁴

¹Programa de Residência Médica em Clínica Médica, Universidade Federal do Triângulo Mineiro (UFTM),

²Unidade de Especialidades Cirúrgicas, Hospital de Clínicas, UFTM,

³Unidade de Laboratório Análises Clínicas e Anatomia Patológica, Hospital de Clínicas, UFTM,

⁴Disciplina de Gastroenterologia, UFTM, Uberaba, MG, Brasil

Abstract The World Health Organization has declared the novel coronavirus disease 2019 (COVID-19) a global public health emergency. Despite the predominating respiratory symptoms occurring in COVID-19, thrombosis can occur in some patients, with morbidity and mortality increase due to the respiratory worsening. This article reports the case of a 62-year-old man with a flu-like illness that was diagnosed as COVID-19 by RT-PCR of SARS-CoV-2. After three weeks, he subsequently developed abdominal pain in addition to bloating, nausea, and vomiting. He underwent exploratory laparotomy after imaging tests suggested mesenteric ischemia. Intestinal ischemia was evident, due to the absence of flow in the superior mesenteric artery and jejunal branches. Embolectomy and enterectomy were performed and they resulted in a favorable outcome, with clinical improvement. This case adds data to the limited literature on extrapulmonary complications of COVID-19, notably those related to thromboembolic events.

Key words: COVID-19, SARS-CoV-2 infection, thromboembolism, mesenteric ischemia, acute abdomen

Resumen *Tromboembolismo de la arteria mesentérica superior y de las ramas yeyunales post-COVID-19*

La Organización Mundial de la Salud ha declarado la enfermedad del nuevo coronavirus 2019 (COVID-19) una emergencia de salud pública mundial. A pesar de los síntomas respiratorios predominantes en COVID-19, la trombosis puede ocurrir en algunos pacientes, con un aumento de la morbimortalidad debido al empeoramiento respiratorio. Presentamos el caso de un hombre de 62 años con enfermedad similar a la gripe que fue diagnosticada como COVID-19 por RT-PCR de SARS-CoV-2. Después de tres semanas, desarrolló dolor abdominal además de hinchazón, náuseas y vómitos. Fue sometido a laparotomía exploradora luego de que las pruebas de imagen sugirieran isquemia mesentérica. Se evidenció isquemia intestinal por ausencia de flujo en la arteria mesentérica superior y ramas yeyunales. Se realizó embolectomía y enterectomía con evolución favorable, con mejoría clínica. Este caso añade datos a la limitada literatura sobre las complicaciones extrapulmonares del COVID-19, en particular las relacionadas con eventos tromboembólicos.

Palabras clave: COVID-19, infección por SARS-CoV-2, tromboembolia, isquemia mesentérica, abdomen agudo

Coronavirus disease 2019 (COVID-19) is a viral infection that originated in Wuhan, China¹. The disease is caused by an enveloped single-stranded RNA beta coronavirus, known as the severe acute respiratory syndrome coronavirus². The World Health Organization declared COVID-19 a global pandemic on March 11, 2020. This disease poses a myriad of challenges to the scientific community. The most reported clinical manifestations

of COVID-19 are fever, myalgia, cough and dyspnea¹. Several pathophysiological mechanisms that could trigger thrombotic phenomena are involved, including endothelial dysfunction, with increased levels of von Willebrand factor; systemic inflammation and a pro-coagulant state achieved through tissue factor pathway activation².

Clinical case

In September 2020, a 62-year-old man was admitted in our hospital owing to severe diffuse abdominal pain for three days associated with nausea, vomiting and a peak fever of 38.5°C. He had been using ceftriaxone and metronidazole for two days. He initially presented with diarrhea but progressed to develop inability to eliminate gas and feces. He had been hospitalized 20 days ago due to pneumonia caused by CO-

Received: 28-XII-2021

Accepted: 9-V-2022

Postal address: Geisa P. M. Gomide, Universidade Federal do Triângulo Mineiro, Avenida Getúlio Guaritá, 130 Bairro Abadia, Uberaba/MG, Brasil ZIP CODE: 38025-440

e-mail: geisa.gomide@uftm.edu.br

VID-19, diagnosed by RT-PCR of SARS-CoV-2, with 80% pulmonary involvement, when he was administered amoxicillin 1500 mg and dexamethasone 8 mg per day, both intravenous, for seven days. The patient also received Enoxaparin 60 mg twice daily subcutaneously for 5 days. The biological marker D-dimer was not measured during hospitalization. When admitted to the emergency unit, after almost three weeks after the onset of condition, he had a flat, semi-distended abdomen with reduced bowel sounds, diffuse pain on palpation, with no signs of peritoneal irritation.

Abdominal computed tomography showed signs of intestinal occlusion, but without identification of an obstructive factor. In addition, it revealed the presence of a thrombus in the middle third of the superior mesenteric artery, 5.5 cm away from the abdominal aortic ostium with partial obstruction of the lumen and without signs of hypoperfusion in the intestinal loops (Fig. 1).

He underwent exploratory laparotomy due to the diagnostic hypothesis of vascular acute abdomen (mesenteric ischemia), with evidence of ischemia in the jejunum segment, 60 cm from the Treitz angle and without any signs of perforation or other

complications. The superior mesenteric artery and jejunal branches were dissected and noticed to be pulseless. Thromboembolectomy was performed, with the clearance of a large amount of material compatible with the embolus/thrombus, resulting in a good pulse after the procedure. Enterectomy of 40 cm segment of the small bowel and primary anastomosis (entero-enteroanastomosis) were performed, and the obtained specimens were sent for histopathological examination.

Microscopic evaluation of the embolectomy product revealed a recent blood thrombus (Fig. 2) that was predominantly fibrinous. Evaluation of the enterectomy product revealed a segment of the small intestine with extensive mucous infarction and the foci of transmural infarction (Fig. 2). Intense acute peritonitis was found, along with increased collagen deposition in the lamina propria, which indicated chronic ischemic enteritis. The clinical picture was suggestive of chronic ischemia followed by acute infarction.

The patient was discharged nine days after his admission, using rivaroxaban 20mg orally, daily. After about two months, he developed anasarca, hyporexia and abdominal pain in addition to hypoalbuminemia. He was diagnosed with short

Fig. 1.— At the top, axial abdominal computed tomography with contrast in the arterial phase. The arrow shows a filling defect (embolus) within the superior mesenteric artery. It is associated with slight densification of adjacent fat. Below, sagittal abdominal computed tomography with contrast in the arterial phase. The arrows point to: (A) the superior mesenteric artery and (B) an embolus inside the superior mesenteric artery.

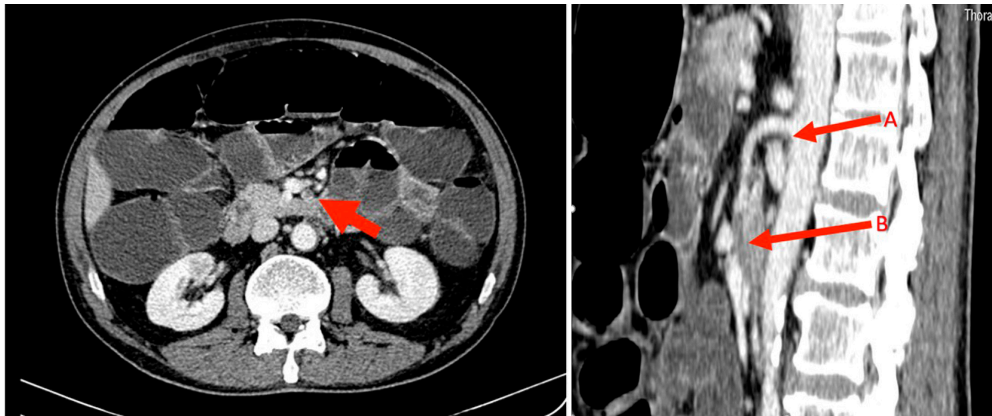
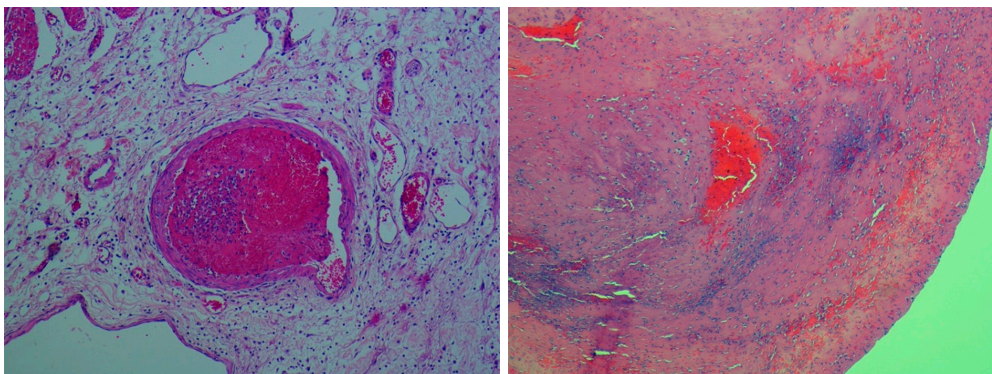


Fig. 2.— At the top, mesenteric blood vessel filled by solidified fibrin with erythrocytes entrapped within forming a thrombus utilizing hematoxylin and eosin stains (100X). Below, extensive coagulative necrosis of the intestine, hemorrhage and acute inflammatory reaction consistent with transmural intestinal infarction (40X).



bowel syndrome. The patient showed significant clinical and nutritional improvement after dietary adjustments, and he is currently under outpatient follow-up with a serum albumin level of 4.3g/dL at the time of writing this report.

In compliance with the Declaration of Helsinki and ethical standards of Brazil, this project was approved by the Research Ethics Committee of the Clinical Hospital - Federal University of Triângulo Mineiro, according to the Brazilian National Health Council resolution no. 466/2012, which deals with human research (CAAE 52716721.8.0000.8667; Approval no. 5.105.301). Written informed consent was obtained from the patient for publication of this case report.

Discussion

The COVID-19 pandemic is a new and rapidly evolving global public health problem. Therefore, reports on the unique aspects of this disease are crucial to help professionals in the management of infected patients¹.

Thrombotic complications associated with COVID-19 have been widely described, mainly venous thromboembolic events. Arterial thrombosis has also been reported, but its prevalence is not well known. At any rate, such reports support the notion that COVID-19 promotes a hypercoagulable state in the body^{1,3}.

During the SARS-CoV-1 epidemic between 2002-2004, the reported incidence rates of deep vein thrombosis and pulmonary thromboembolism were 20% and 11%, respectively. In comparison, the incidence of thrombotic complications in patients with COVID-19 has been reported to be as high as 79%³. In an autopsy study of 12 patients who died from COVID-19, a high incidence of deep vein thrombosis (58%) was found. Furthermore, diffuse alveolar damage was demonstrated by histology in 67% of cases². In a Dutch study of 184 critically ill patients with COVID-19, 31% developed thrombotic complications, with pulmonary thromboembolism being detected in 27% of cases and ischemic stroke in 3.7%⁴.

COVID-19-related hypercoagulability is likely to have a multifactorial etiology. First, it is related to viral aggression on the endothelial cells, which leads to inflammation and an increase in pro-coagulant factors, such as factor VIII, von Willebrand factor and fibrinogen. Moreover, it is associated with a storm of cytokines that trigger coagulation and activation of fibrinolysis^{1,2}. Second, additional factors associated with hypercoagulability may be related to the presence of circulating prothrombotic microvesicles, consisting of nuclear DNA, histones, and nucleosomes, identified as cytoplasmic microparticles derived from platelets, monocytes, or neutrophils^{2,3}. A third possible mechanism involves the of angiotensin-converting enzyme 2 (ACE-2) receptors used by the virus to entry in human cells, including endothelial, lung and enterocyte cells, that triggering the same inflammatory phenomenon mentioned

above⁵. In addition, there is an increase in the levels of angiotensin-II, which also exerts prothrombotic effects, including vasoconstriction and platelet and endothelial activation⁶.

This article reports a case of acute mesenteric ischemia in a post-COVID-19 patient, which is considered a severe and rare abdominal emergency, usually requiring an urgent surgical approach and a wide intestinal resection. A prompt diagnosis is essential for successful treatment¹. Delays in the diagnosis of acute mesenteric ischemia are common and are associated with high rates of morbidity and mortality. Prompt diagnosis requires a high index of suspicion and early contrast-enhanced computed tomography imaging¹. Treatment of this condition relies on gastrointestinal decompression, fluid resuscitation, hemodynamic support, surgical resection of the necrotic bowel, and restoration of blood flow to the ischemic intestine. The diagnosis of an ischemic bowel should be one of the top differentials in critically ill patients when clinical symptoms are suggestive¹. Mesenteric venous thrombosis is a rare condition, estimated to occur in 0.002-0.06% of all hospital admissions. Unlike mesenteric arterial thrombosis, it is associated with prothrombotic and primary states of hypercoagulability. Thrombosis in atypical sites associated with COVID-19 has also been described, however, the frequency of its occurrence is not known.⁷⁻¹¹

Early evaluation of abdominal vessels in COVID-19 patients who present with abdominal symptoms should be considered, especially when there is an elevated D-dimer level, as early treatment of thrombosis with low-molecular-weight heparin can have a significant impact on the therapeutic outcome⁸.

The present case supports the hypothesis of a hypercoagulable state related to COVID-19. Current treatment recommendations include the prophylactic use of low molecular weight heparin, which also has anti-inflammatory properties and is recommended by several international guidelines^{3,4}.

Conflicts of interest: None to declare

References

1. Singh B, Mechineni A, Kaur P, et al. Acute intestinal ischemia in a patient with COVID-19 infection. *Korean J Gastroenterol* 2020; 76: 164-6.
2. Wichmann D, Sperhake JP, Lütgehetmann M, et al. Autopsy findings and venous thromboembolism in patients with COVID-19: A prospective cohort study. *Ann Intern Med* 2020; 173: 268-77.
3. Kichloo A, Dettloff K, Aljadah M, et al. COVID-19 and hypercoagulability: A review. *Clin Appl Thromb Hemost* 2020; 26: 1076029620962853.
4. Klok FA, Kruip MJHA, Van der Meer NJM, et al. Incidence

- of thrombotic complications in critically ill ICU patients with COVID-19. *Thromb Res* 2020; 191: 145-7.
5. Thuluva SK, Zhu H, Tan MML, et al. A 29-year-old male construction worker from India who presented with left-sided abdominal pain due to isolated superior mesenteric vein thrombosis associated with SARS-CoV-2 infection. *Am J Case Rep* 2020; 21: e926785.
 6. Franchini M, Marano G, Cruciani M, et al. COVID-19-associated coagulopathy. *Diagnosis (Berl)* 2020; 7: 37-363.
 7. Carmo Filho A, Cunha BS. Inferior mesenteric vein thrombosis and COVID-19. *Rev Soc Bras Med Trop* 2020; 53.
 8. Azouz E, Yang S, Monnier-Cholley L, Arrivé L. Systemic arterial thrombosis and acute mesenteric ischemia in a patient with COVID-19. *Intensive Care Med* 2020; 46: 1464-5.
 9. Piazza G, Morrow DA. Diagnosis, management, and pathophysiology of arterial and venous thrombosis in COVID-19. *JAMA* 2020; 324: 2548-9.
 10. Cheung S, Quiwa JC, Pillai A, Onwu C, Tharayil ZJ, Gupta R. Superior mesenteric artery thrombosis and acute intestinal ischemia as a consequence of COVID19 infection. *Am J Case Rep* 2020; 21: 1-3.
 11. Chen C, Li YW, Shi PF, Qian SX. Acute Mesenteric Ischemia in Patients with COVID-19: Review of the literature. *J Natl Med Assoc* 2022; 114: 47-55.