

EBER + EXTRANODAL NK/T LYMPHOMA IN PATIENT WITH IDIOPATHIC CD4 LYMPHOCYTOPENIA

FEDERICO S. CATALDO¹, FERNANDO WARLEY¹, VICTORIA OTERO¹,
DANA KOHAN², SILVINA ODSTRCIL¹, ERIKA BRULC¹

¹Sección de Hematología, ²Servicio Anatomía Patológica, Hospital Italiano de Buenos Aires, Argentina

Abstract Idiopathic CD4 lymphocytopenia (ICL) not related to HIV is an infrequent and severe condition with no etiology defined until now. The concomitant presence of an underlying disease, especially an oncohematological process, could be related to the immune physiopathology and the development of the immunosuppressive state. On the other hand, Epstein Barr virus is a well-known oncogenic pathogen described in the development of several types of lymphoma which might be reactivated in the ICL. There is still no specific treatment for this syndrome, so the therapeutic scope for these patients is the treatment of opportunistic diseases and the administration of specific antimicrobials as prophylaxis. We present a patient with an uncommon association of an ICL and an extranodal T/NK lymphoma with detection of VEB nuclear RNA by *in situ* hybridization (EBER). Diagnosis was challenging which led the health team to carry out many studies over several months

Key words: T-lymphocytopenia, idiopathic CD4-positive T-lymphocytopenia, Epstein-Barr virus infections, lymphoma, extranodal T-NK-cell

Resumen *Linfoma T/NK EBER positivo en paciente con linfocitopenia CD4 idiopática.* La linfocitopenia CD4 idiopática (ICL) no relacionada al HIV es una condición grave e infrecuente sin una etiología aún definida. La presencia de una enfermedad subyacente, especialmente un proceso oncohematológico, podría tener relación en la fisiopatología del proceso inmunológico. Por otro lado, el virus Epstein Barr (VEB) es bien conocido por ser un patógeno oncogénico descrito en el desarrollo de diversos tipos de linfomas, el cual podría ser reactivado en estados de inmunosupresión severa. No existe aún un tratamiento específico para este síndrome, por lo que el objetivo terapéutico en estos pacientes radica en el manejo profiláctico y activo de las distintas enfermedades oportunistas ante las cuales son susceptibles. Se presenta un paciente con un déficit grave de linfocitos CD4 de causa idiopática, y un diagnóstico posterior de linfoma T/NK extraganglionar con detección de RNA nuclear de VEB por hibridación *in situ* (EBER), una asociación poco descrita en la literatura médica.

Palabras clave: linfocitopenia-T, linfocitopenia T idiopática CD4-positiva, infecciones por virus Epstein-Barr, linfoma, célula T-NK extraganglionar

Idiopathic CD4 lymphocytopenia (ICL) is considered a rare immunological condition reported in 1993 by Smith DK. and col in the first cohort of individuals with this pathology¹. The ICL is defined by a T CD4 + cell count lower to 300/mm³, more than once over a sustained period of 2 to 3 months; or less to 20% of the total amount of lymphocytes. Such findings must occur in the absence of a HIV-1 or HIV-2 infection (the main cause of T immunodeficiency), some other type of congenital immunodeficiency or therapeutic immunomodulatory process that justifies the pathological state².

The physiopathology of the disease still is a theme of debate. Since the 1990s studies revealed ICL is a rare ill-

ness, non-emergent and is not caused by any known virus, being different to HIV in its clinical, immunological and epidemiology characteristics³. Besides, from biological point of view, an overexpression of CD95 and a decrease of co-receptor CXCR4 could explain the increment in the apoptosis of CD4 T cells in these patients⁴.

Cellular immunity mainly lies in the functioning of T cells against abnormal or infected cells, by cytotoxicity or apoptosis induction. This process is developed by T CD8 cells and natural killer lymphocytes. The CD4 cells generate chemical mediators that trigger most of these processes activating the effector cells. This cell line depletion can generate a very severe predisposition to opportunistic infections and onco-hematological pathologies, with a high mortality rate². However, it is important to highlight that B lymphocytes are not usually affected in ICL, so the immunoglobulin levels and humoral immunity is normal in most patients¹.

Received: 19-VIII-2020

Accepted: 15-XII-2020

Postal address: Federico S. Cataldo, Hospital Italiano de Buenos Aires, Tte. General J. D. Perón 4190, 1199 Buenos Aires, Argentina
e-mail: federico.cataldo@hospitalitaliano.org.ar

Epstein Barr virus (EBV) is a well-known oncogenic pathogen described in the development of several types of lymphoma. The first case of clinical importance associated with EBV was a B lymphoma described in 1956 by D. Burkitt in an epidemic report occurring in African children⁵. Time later the association between NK/T lymphomas was documented⁶. The relationship of a latent infection of this herpesvirus and the development of ICL was and is nowadays an object of study to explain the physiopathology of immunological pathology.

We present a patient with an idiopathic severe deficit of CD4 lymphocytes with a later diagnosis of an EBV + extranodal T/NK lymphoma, an uncommon association reported in medical literature.

Case report

A 77-year-old male with a history of Parkinson's disease undergoing levodopa treatment, who began studies in August 2019 by symptoms of asthenia, adinamia and progressive weight loss of approximately 8 months of evolution, associated with oropharyngeal candidiasis diagnosed by upper gastrointestinal videoendoscopy. At the time of admission, the laboratory showed severe lymphopenia, with less than 6% of leukocyte counts (8200 cell/mm³), with an absolute count of 450 cell/mm³ with no further alterations in the blood count (hematocrit 39.3%, platelets 363 000 cell/mm³). During hospitalization additional tests were performed: viral serological tests were all negative including HIV, HBV, HCV HTLV and CMV, no vitamin deficiencies were presented, celiac disease antibodies were negative and gammaglobulines levels between normal range (1.45 g/dl). B and T cells subpopulation were studied, finding a CD4 lymphocyte count of 14% and an absolute count of 85 cells/mm³ (reference value 800-1200). A bone marrow biopsy and a PET-CT scan were performed, considering a possible underlying oncohaematological disease. Bone marrow biopsy did not identify abnormal cells related to clonal process and PET-CT just revealed small non-specific cervical and mediastinal nodes with low uptake. The patient continued with ambulatory controls.

Two months later, he was admitted to the emergency room due to a 12-hour evolution, sharp abdominal pain, with peritoneal reaction signs and stiffness of the abdominal wall. He had no fever, nausea, vomiting or any other related symptoms. A CT scan showed signs of pneumoperitoneum, parietal thickening of the small intestines associated with an alteration of the adjacent fat planes, with no clear view of the appendix. A surgical intervention was carried out with an exploratory laparotomy, after which a purulent peritonitis was diagnosed. The patient presented a pointed injury to the terminal ileum, therefore a 10 cm intestine resection was made, together with a subsequent enteroanastomosis. After a long-lasting postoperative period, with multiple infectious complications, the patient was released to home care.

The pathology report of the surgical material showed a large ulcerated injury containing pathological lymphocytic infiltration mainly by intermediate to large sized cells with moderate pleomorphism, arranged in clusters, associated to lymph nodes with distortion of their histoarchitecture at the expense of an expansion of CD8 T cells. Immunohistochemistry showed positivity with CD3, CD8, Granzyme, CD30 and CD56; resulting negative with CD20, CD4 (with positive control in macrophages), and ALK. The technique of *in situ*

hybridization for the detection of EBV was carried out with an EBER 1 DNP probe (Ventana, Roche), being intensely positive (Fig.1). A molecular study of T lymphoid clonality with PCR technique was carried out showing monoclonal rearrangement of the TCR gamma receptor in the VJA segments of the gene that encodes this receptor (TCR Gamma Rearrangements Molecular Analysis Kit, Master Diagnóstica, Spain). These results led to a diagnosis of EBV + extranodal T/NK lymphoma with nasal phenotype⁷.

During this last hospitalization a new CD4 cells dosing was conducted, being the value of 54 cell/mm³, which were even lower than the previous ones. EBV serology was also tested, being positive for IgG, however, its viral load was not detectable.

Due to the poor general clinical condition of the patient after the long-term hospitalization, in addition to the chronic comorbidities and a performance status >2, he was not considered suitable for high intensity systemic chemotherapy. Finally, it was agreed to continue palliative care at home, dying 4 months later as a result of disease progression.

Discussion

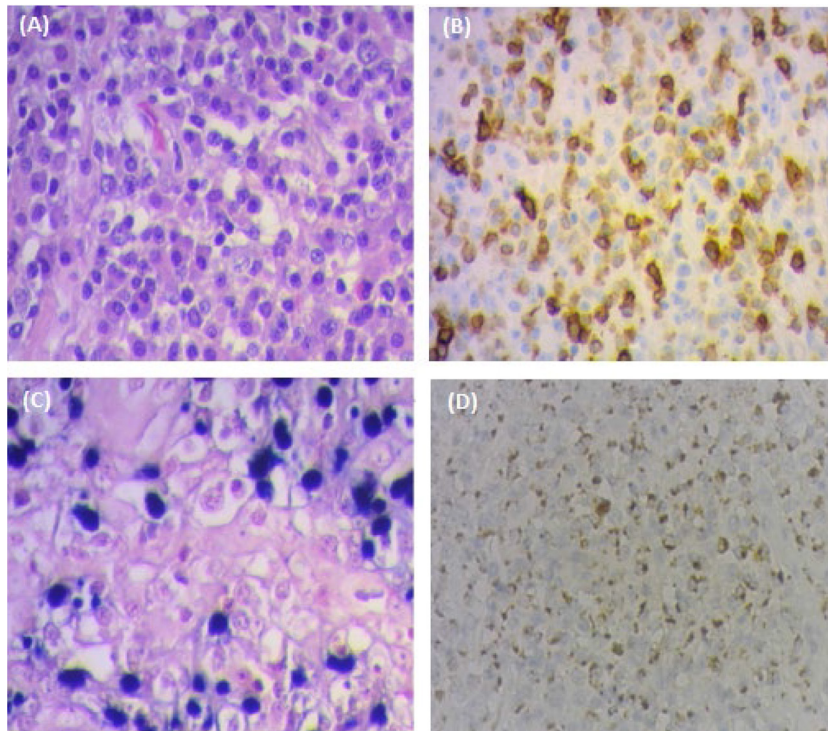
The exact pathophysiology of ICL is currently unknown but it is understood that it should be due to the combination of multiple immunological disorders such as an inefficient production, an increase of the destruction and tissue sequestration of T lymphocytes⁸. The main hypothesis focuses on a defective cytokine production of tumor necrosis factor alpha or gamma-interferon that would lead to a decrease in the CD4 cell lymphogenesis and an increase in its apoptosis^{8,9}.

Its clinical presentation distinguishes itself by the emergence of opportunistic severe diseases such as the widespread cryptococcal disease, atypical mycobacterial infections, Pneumocystis pneumonia or oropharyngeal candidiasis. There have also been cases of progressive multifocal leukoencephalopathy, autoimmune pathologies and oncohaematological processes such as Kaposi's sarcoma or different types of lymphomas⁴.

There is still no specific treatment for this syndrome, although diverse alternatives have been developed to increase and promote the CD4 cell pool, as in the case of the administration of IL-2, IFN and IL-7⁸. Stem cell transplantation would be another option, but only for specific cases. The therapeutic standard for these patients is the treatment of opportunistic diseases and the administration of specific antimicrobials (as indicated in patients with HIV) for prophylaxis¹⁰.

During the last 20 years, few case reports have associated ICL with the appearance of lymphomas, without having a predominant lymphoma subtype. It is striking how in most of them, as in our case, the lymphoproliferative process was associated with EBV, which shows the immune compromise in this group of patients¹¹. Regarding the pathophysiological mechanism, we could hypothesize that the inflammatory cytokines alteration could lead to a decrease of CD4+ T lymphocytes, which would gener-

Fig. 1.– Fig. 1.– Lymph node in terminal ileum biopsy



(A): Hematoxylin and eosin tinction of lymphoid tissue, 10x. (B): Immunohistochemistry showing CD3 positive cells, 10x. (C): Detection of VEB nuclear RNA in neoplastic cells by in situ hybridization technique (EBER) 40x. (D): Positive granzymemarcation in pathological cells, 4x

ate a lower cytotoxic T response, necessary to avoid a reactivation of latent EBV in host cells, which would finally contribute to lymphomagenesis⁸.

Currently, the World Health Organization in its 2016 review of lymphoid neoplasms classified extranodal T/NK lymphomas of the nasal type within the group of mature T and NK neoplasms⁷. The diagnosis is made by pathological anatomy of the lesion where a marked vascular involvement and abundant inflammatory component is seen with the presence of lymphocytes of variable sizes, mixed with eosinophils, plasmocytes or histiocytes. Immunohistochemistry is positive for CD2, cytoplasmic CD3 and CD56, in addition to cytotoxic molecules such as perforin and granzyme¹². Treatment consists of polychemotherapy with or without the combination of radiotherapy; regimens such as the SMILE scheme using a combination of methotrexate, etoposide, asparaginase and ifosfamide are commonly used¹³.

We present this case report because there are few documented evidence of ICL associated with EBER+ extranodal T/NK lymphoma^{14,15}. As it does not have a specific treatment or a clear pathogenesis of the process, clinical suspicion is of vital importance for an early diagnosis that helps to prevent opportunistic infections and oncohematological processes in advanced stages.

Conflict of interest: None to declare

References

1. Smith DK, Neal JJ, Holmberg SD. Unexplained opportunistic infections and CD4 T-lymphocytopenia without HIV infection: An investigation of cases in the United States. *N Engl J Med* 1993; 328: 373-9.
2. Hu Z, Zou Q, Su B. Regulation of T cell immunity by cellular metabolism. *Front Med* 2018; 12: 463-72.
3. Fauci AS. CD4+ T-Lymphocytopenia without HIV Infection: no lights, no camera, just facts. *N Engl J Med* 1993; 328: 429-31.
4. Régent A, Autran B, Carcelain G, et al. Idiopathic CD4 lymphocytopenia: clinical and immunologic characteristics and follow-up of 40 patients. *Medicine (Baltimore)* 2014; 93: 61-72.
5. Burkitt D. A sarcoma involving the jaws in African children. *Br J Surg* 1958; 46: 218-23.
6. Hue SS-S, Oon ML, Wang S, Tan SY, Ng SB. Epstein-Barr virus-associated T- and NK-cell lymphoproliferative diseases: an update and diagnostic approach. *Pathology* 2020; 52: 111-27.
7. Swerdlow SH, Campo E, Pileri SA, et al. The 2016 revision of the World Health Organization classification of lymphoid neoplasms. *Blood* 2016; 127: 2375-90.
8. Zonios D, Sheikh V, Sereti I. Idiopathic CD4 lymphocytopenia: a case of missing, wandering or ineffective T cells. *Arthritis Res Ther* 2012; 14: 222.
9. Sheikh V, Porter BO, DerSimonian R, et al. Administration

- of interleukin-7 increases CD4 T cells in idiopathic CD4 lymphocytopenia. *Blood* 2016; 127: 977-88.
10. Yarmohammadi H, Cunningham-Rundles C. Idiopathic CD4 lymphocytopenia. *Ann Allergy Asthma Immunol* 2017; 119: 374-8.
 11. Kojima M, Sakurai S, Morita Y, Nakamura N, Sugihara S, Shimano SI. EBV(+) B-cell lymphoproliferative disorder associated with subsequent development of Burkitt lymphoma in a patient with Idiopathic CD4(+) T-lymphocytopenia. *J Clin Exp Hematop* 2008; 48: 55-9.
 12. Tse E, Kwong YL. The diagnosis and management of NK/T-cell lymphomas. *J Hematol Oncol* 2017; 10: 85.
 13. Kwong YL, Kim WS, Lim ST, et al. SMILE for natural killer/T-cell lymphoma: analysis of safety and efficacy from the Asia Lymphoma Study Group. *Blood* 2012; 120: 2973-80.
 14. Sasidharanpillai S, Khader A, Puravoor J, Riyaz N. Cutaneous T-cell non Hodgkin lymphoma in a patient with idiopathic CD4 lymphocytopenia. *Indian J Dermatol Venereol Leprol* 2013; 79: 831-3.
 15. Moreno M, Pierzchalski J, Vereza M, Ivanov M, Torchiari F. Linfoma extraganglionar de células T/NK presentación de un caso clínico y revisión de la literatura. *Arch Argent Dermatol* 2014; 64: 57-60.