

HERPESVIRUS 6 TRACHEOBRONCHITIS

INDALECIO CARBONI BISSO¹, LEINIKER NAVARRO REY¹,
JULIETA GONZÁLEZ ANAYA¹, PAOLA X. DE LA IGLESIA NIVEYRO²,
IGNACIO FERNÁNDEZ CEBALLOS¹, MARCOS LAS HERAS¹

¹Terapia Intensiva de Adultos, ²Anatomía Patológica,
Hospital Italiano de Buenos Aires, Buenos Aires, Argentina

E-mail: indalecio.carbonibisso@hospitalitaliano.org.ar

A 39-year-old male patient was admitted to the ICU with acute respiratory failure and required mechanical ventilation. He had a history of severe immunosuppression due to chronic myeloid leukemia treated with nilotinib, as well as a prolonged postoperative hospitalization after a deceased-donor kidney transplant for membranoproliferative glomerulonephritis. To address humoral rejection, he received multiple pulses of methylprednisolone and thymoglobulin. Chest computed tomography revealed hazy opacities in both upper lobes and small nodules with a centrilobular distribution, indicating an inflammatory/infectious process.

A video-bronchoscopy and a bronchoalveolar lavage (BAL) was performed. During the exploration of the air-

way, grouped vesicles on an erythematous base were observed in the lower third of the trachea, extending into the right main bronchus and the right upper lobe. Additionally, a shallow ulceration was noted in the apical segment (B1) of the right upper lobe. The remaining sections of the bronchial tree appeared unaffected (Fig. 1 and Video).

Real-time polymerase chain reaction of BAL fluid detected the presence of Human Herpesvirus 6 DNA. BAL cytology revealed inflammatory smears with polymorphonuclear cells (76%), lymphocytes (14%) and macrophages (10%), isolated cells with nuclear clearance and no evidence of multi-nucleation or classic cytopathic viral inclusions (Fig. 2).

Figura 1 |

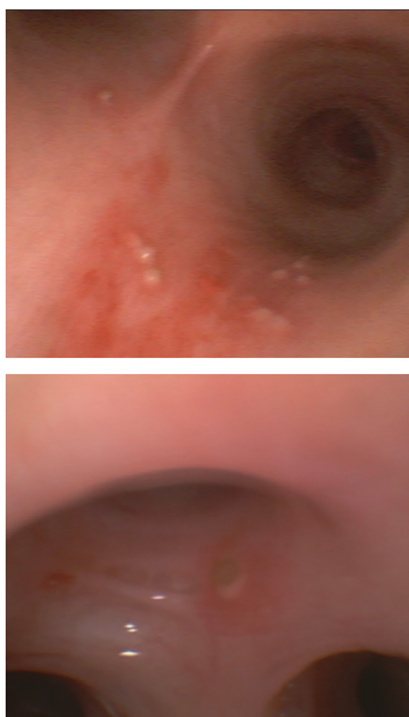


Figura 2 |

